ANIL AGGRAWAL'S
Internet Journal of Forensic Medicine and Toxicology
The world's first online journal devoted entirely to forensic medicine and toxicology · Published 1 January and 1 July

VOL. 3, NO. 2
Downloaded from www.anilaggrawal.com · ISSN 0972-8074 (Online) · https://www.anilaggrawal.com/ij/vol_003_no_002/others/thesis_avneesh/photographs.html

Photographs from Avneesh Thesis

Chapters at a glance

[chapter 1] [chapter 2] [chapter 3] [chapter 4]

chapter 5 [Part 1] [Part 2] [Part 3] [Part 4] [Part 5] [Part 6]

[chapter 6] [chapter 7] [chapter 8] [chapter 9] [Photographs]

Back to the journal

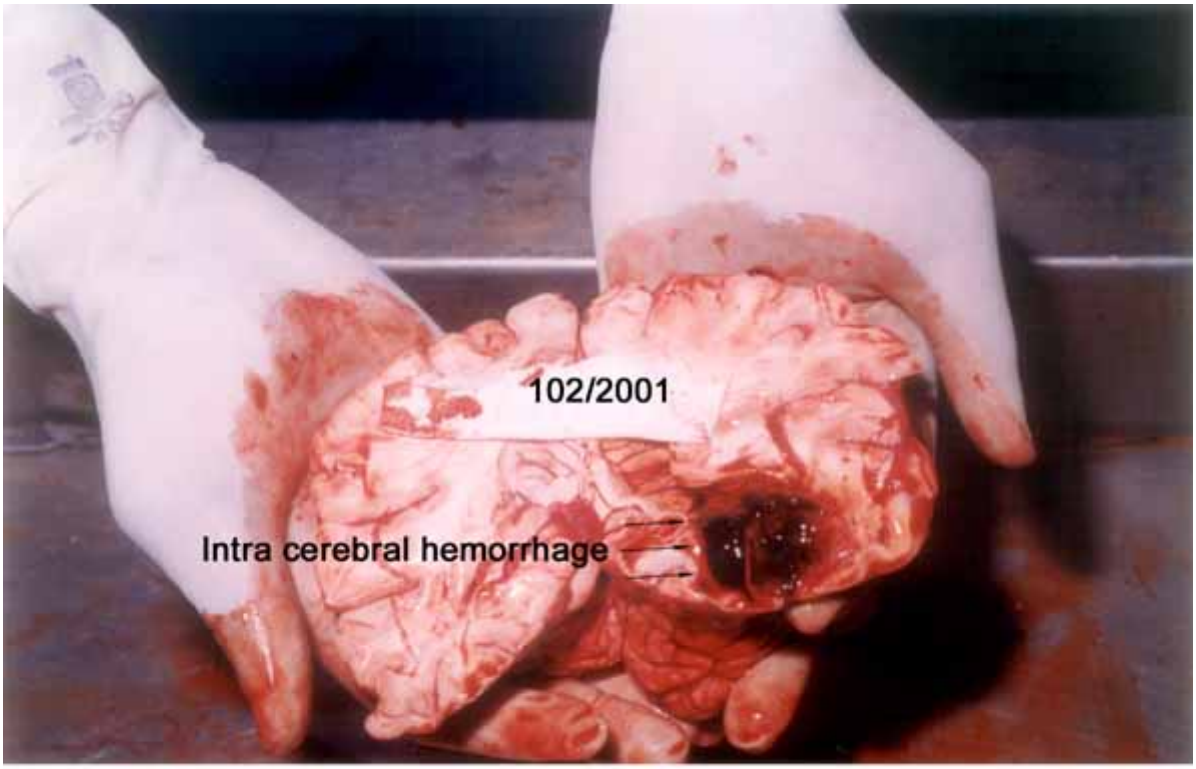

Color Photograph showing Intra cerebral hemorrhage in right temporal lobe

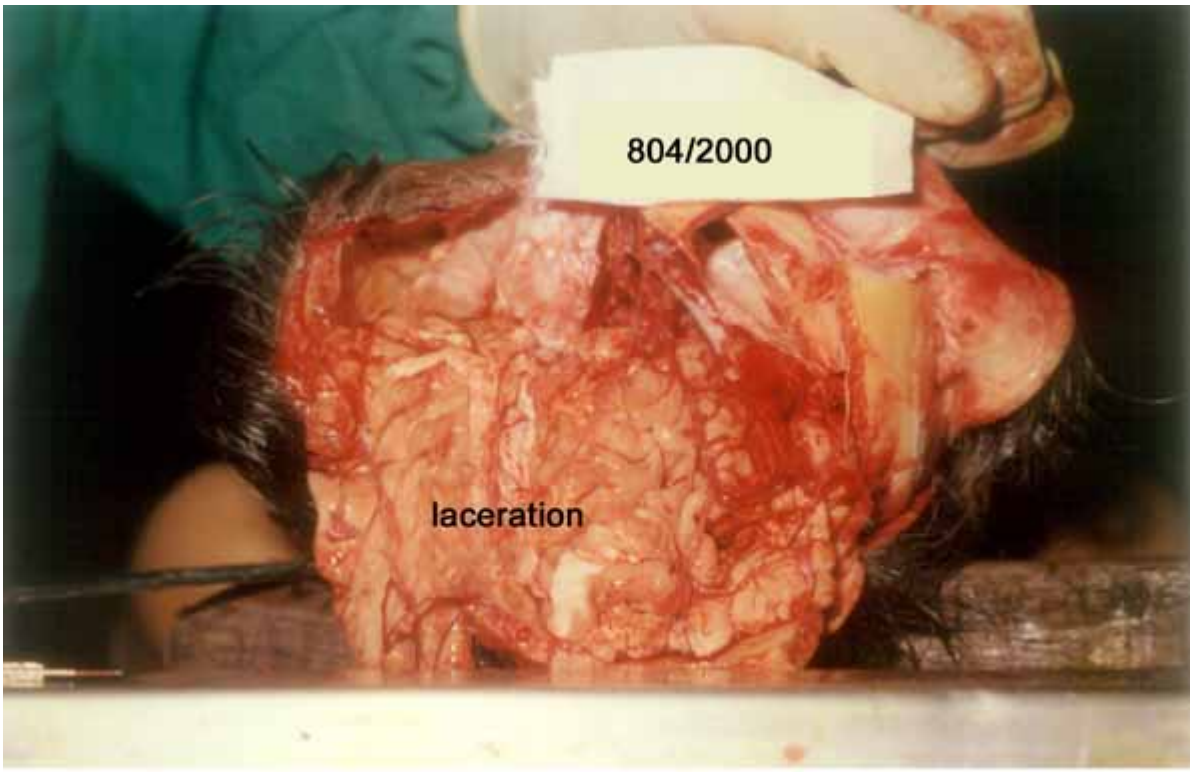

Color Photograph showing laceration of brain along with crush injury of skull

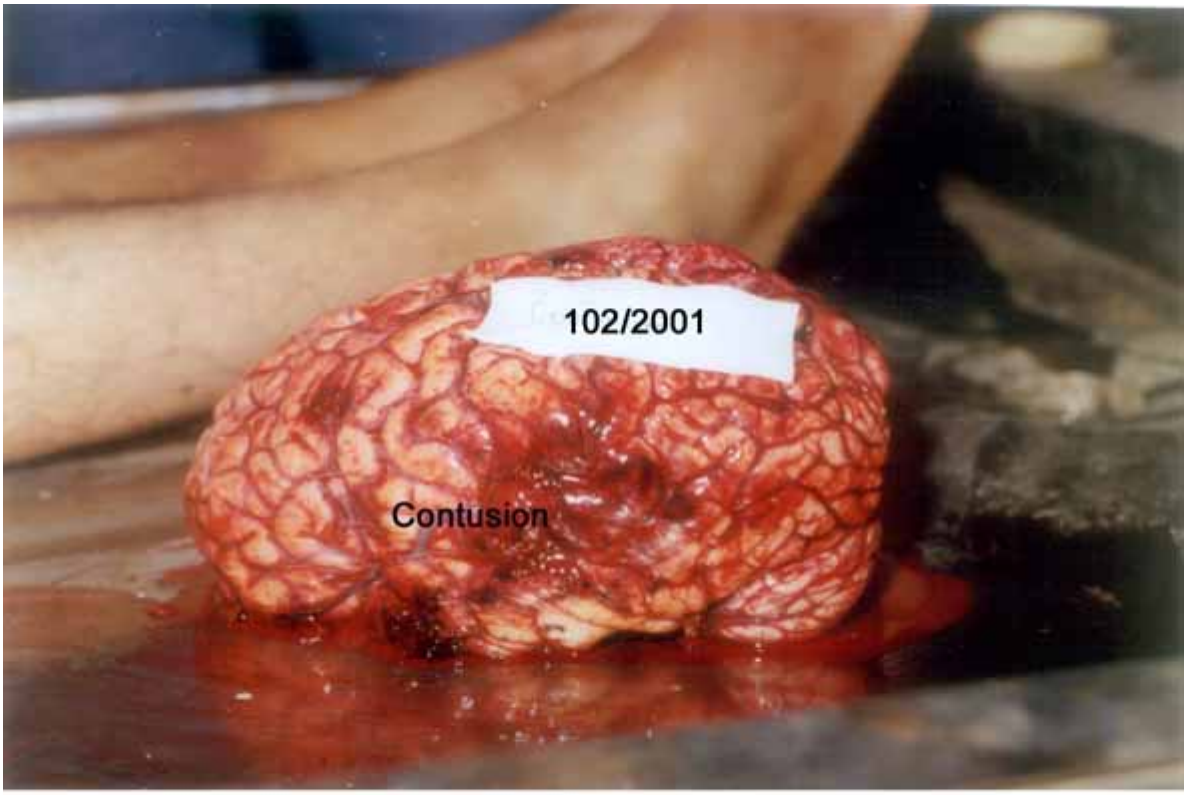

Color Photograph showing Contusion over right temporal lobe

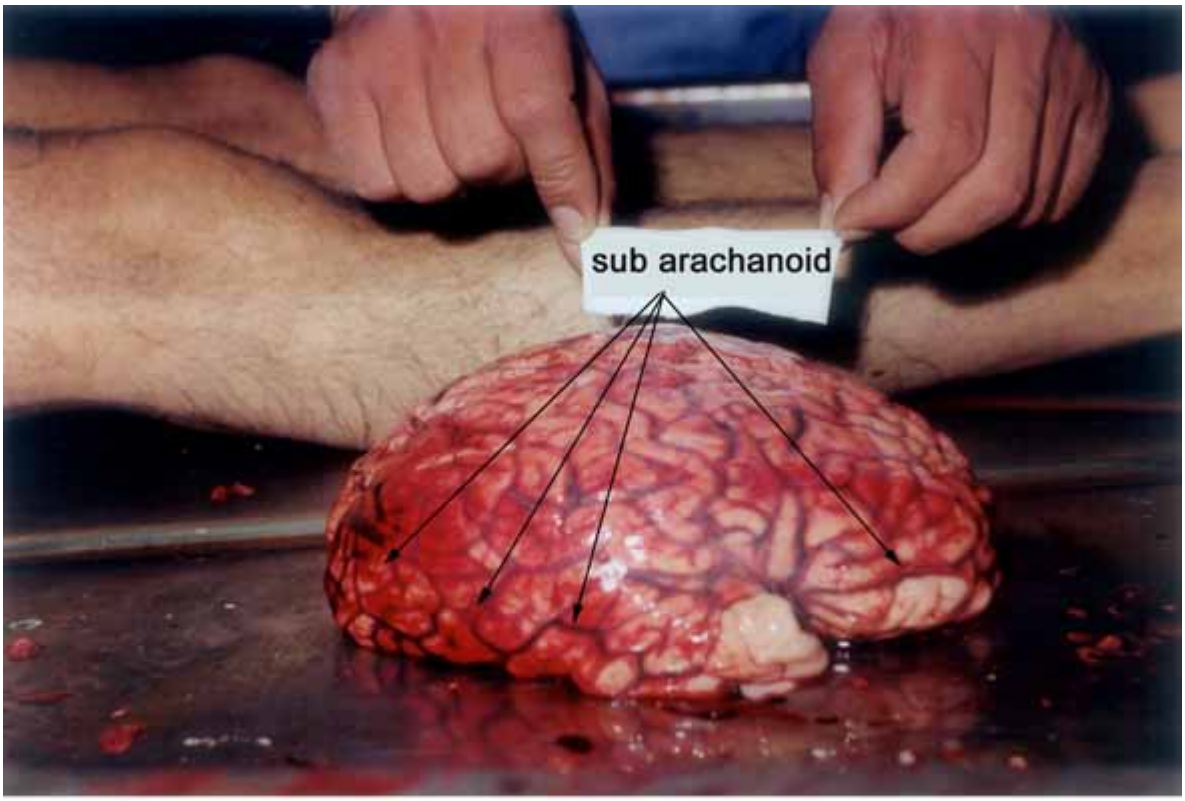

Color Photograph showing sub arachanoid hemorrhage over right frontal, temporal and occipetal lobe

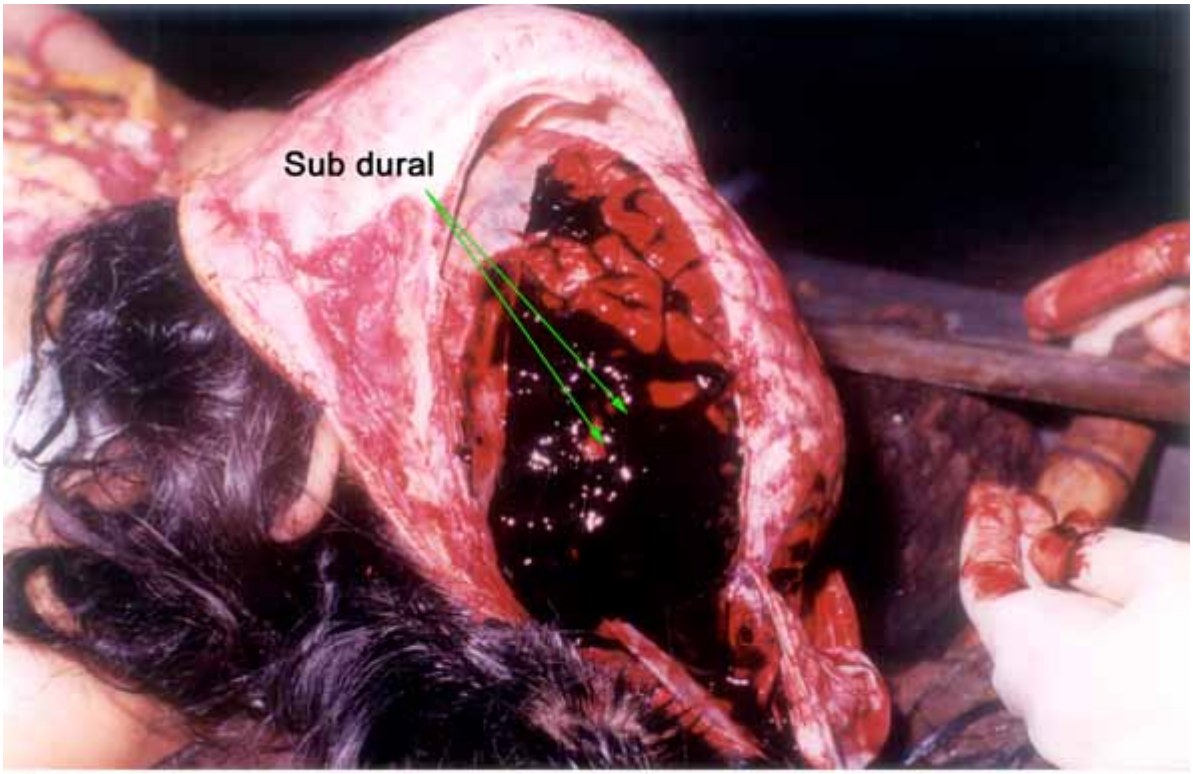

Color Photograph showing Sub dural hemorrhage over left parietal region

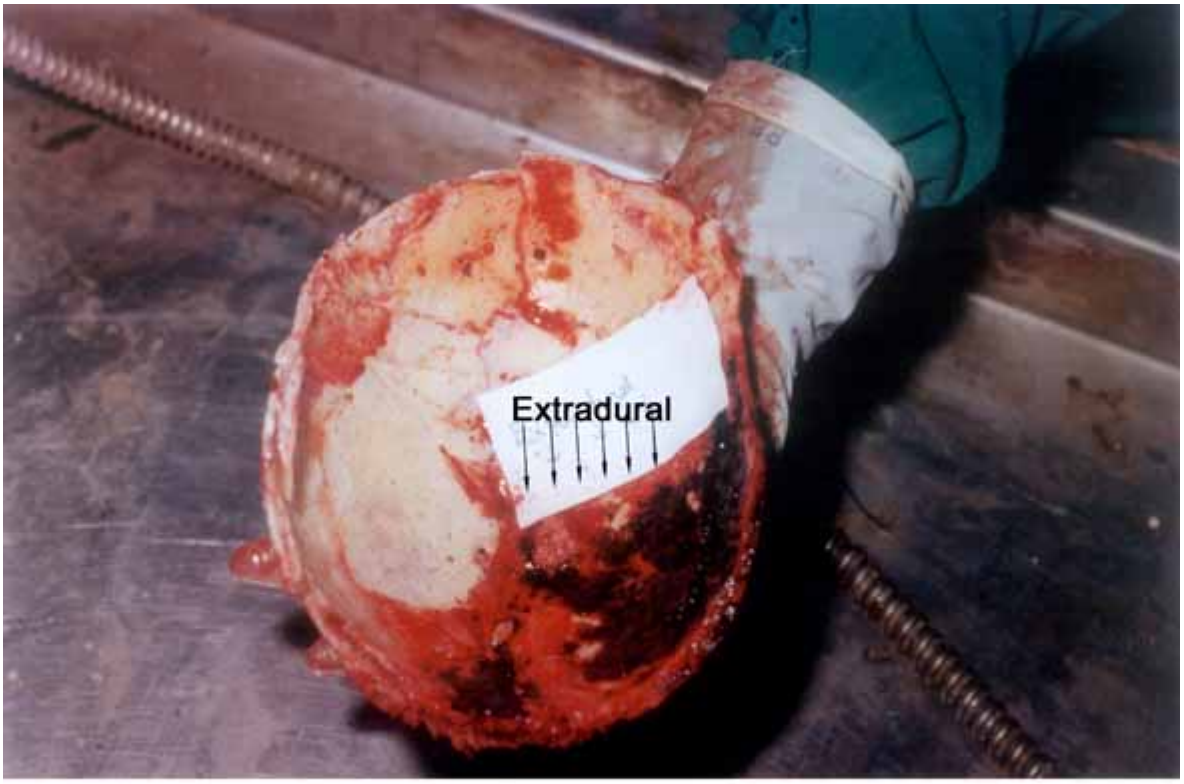

Color Photograph showing Extradual hemorrhage in vault of skull

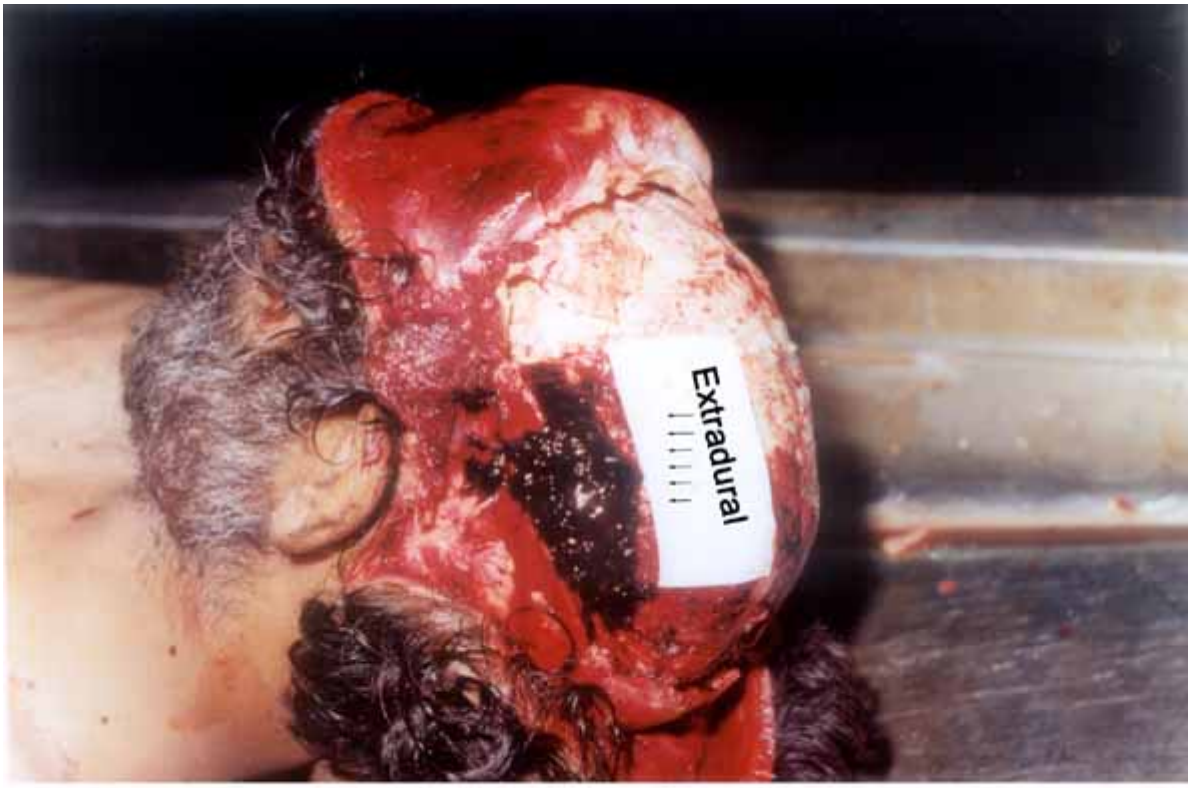

Color Photograph showing Extradural hemorrhage over left temporal region

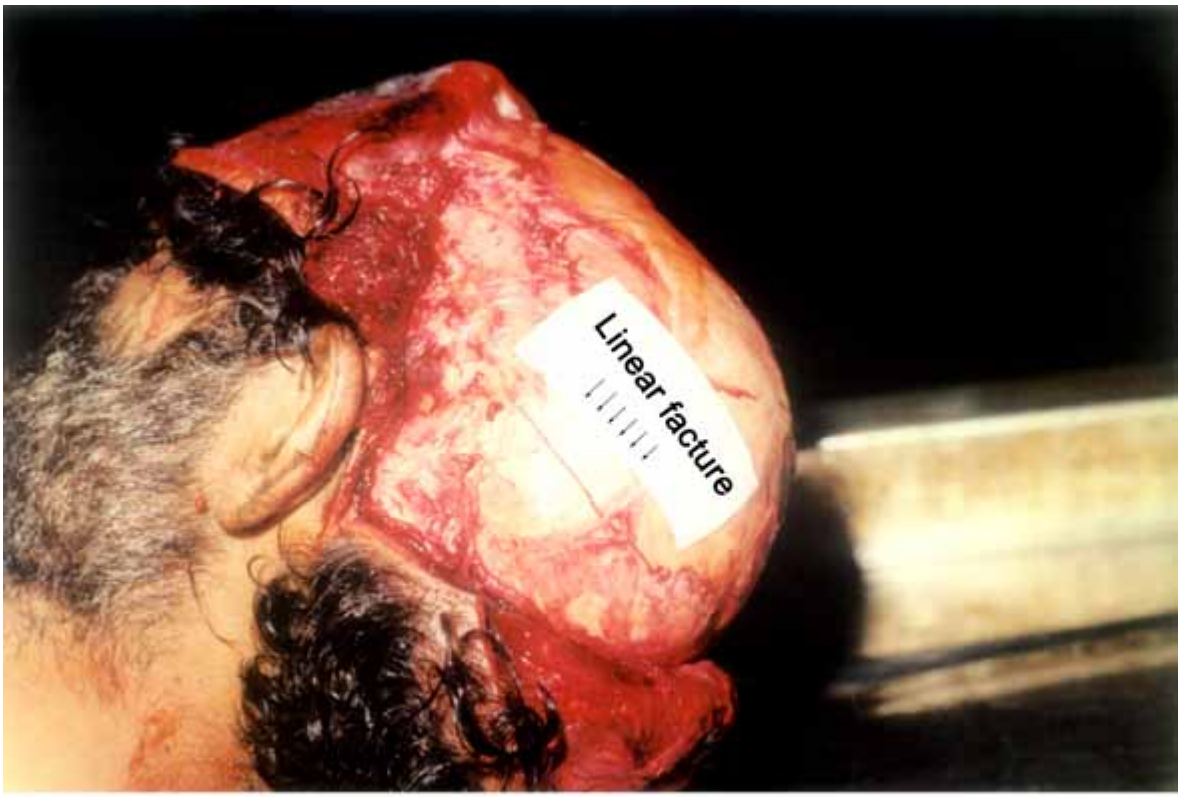

Color Photograph showing linear fracture of left parietal and temporal bone

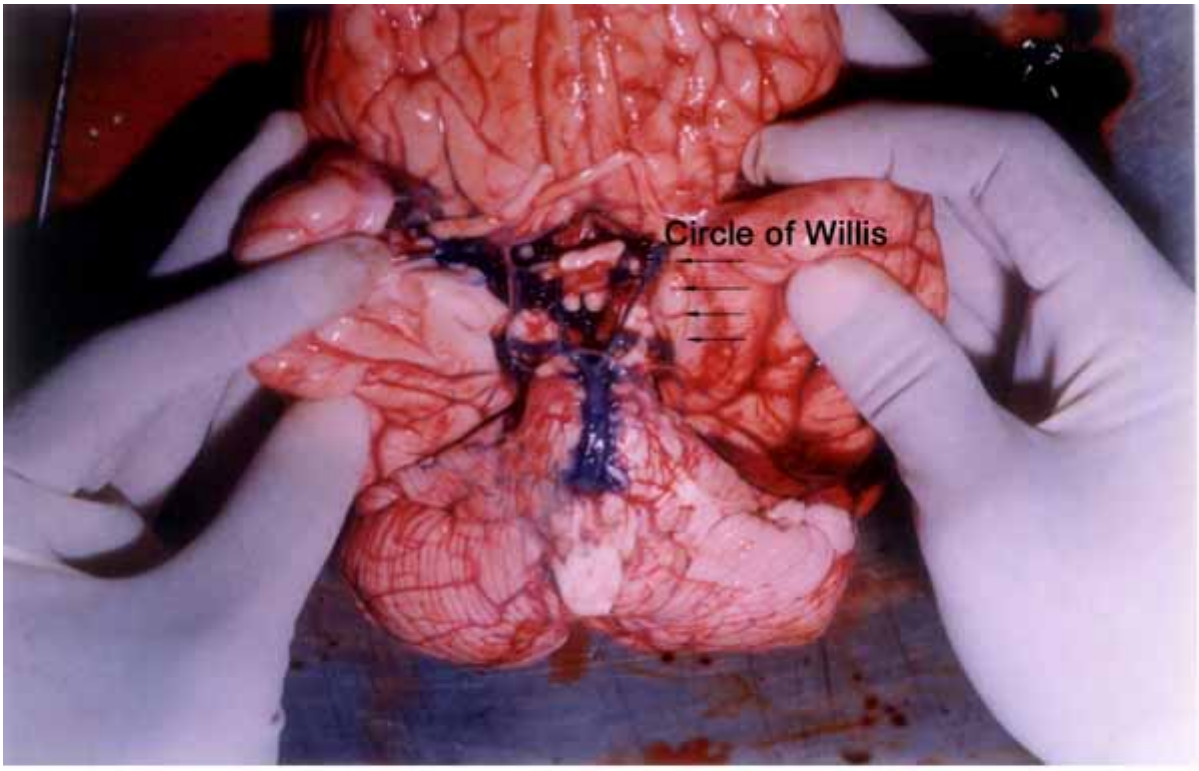

Color Photograph showing visualisatiion of Circle of Willis after injection of Indian ink



Color Photograph showing laceration of scalp

Back