ANIL AGGRAWAL'S
Internet Journal of Forensic Medicine and Toxicology
The world's first online journal devoted entirely to forensic medicine and toxicology · Published 1 January and 1 July

VOL. 11, NO. 2 · JULY – DECEMBER 2010
Downloaded from www.anilaggrawal.com · ISSN 0972-8074 (Online) · https://www.anilaggrawal.com/ij/vol_011_no_002/papers/paper003.html

An Unusual Case of Hanging

Mukta Rani, Rohit, Ankita Dey, P.C. Dikshit

Assistant Professor, Department of Forensic Medicine, Lady Hardinge Medical College, New Delhi, India
Medical Officer, Deptt. of General and Forensic Psychiatry, Institute of Mental Health, Singapore
Senior Resident, Department of Forensic Medicine, Maulana Azad Medical College, New Delhi, India
Director Professor, Department of Forensic Medicine, Maulana Azad Medical College, New Delhi, India
Contact: the corresponding author Mukta Rani · dr_mukta2004@yahoo.co.in

CITE THIS ARTICLE

Rani M, Rohit, Dey A, Dikshit PC. An Unusual Case of Hanging. *Anil Aggrawal's Internet Journal of Forensic Medicine and Toxicology* [serial online], 2010; Vol. 11, No. 2 (July – December 2010): [about 8 p]. Available from: https://www.anilaggrawal.com/ij/vol_011_no_002/papers/paper003.html

ABSTRACT

Hanging is a common mode of suicide and homicidal hanging is rare and is usually possible in the children, thin, elderly and in adults under the influence of drugs or alcohol. We here present a case that appeared like homicidal hanging due to the unusual presence of the ligature material around the face and neck. On detailed examination and from circumstantial evidence it was found to be suicidal. A thorough autopsy examination of the body and meticulous examination of the scene are crucial in such cases where there is doubt regarding the manner of hanging.

Keywords: Homicide, suicide, hanging, asphyxia

Introduction

Hanging is one of the most commonly used methods for suicide worldwide.[1] Hanging can be suicidal which is most common but cases of accidental hanging and rarely of homicidal hanging have been reported. There have been rare but reported cases where people have tried to stage a suicide as homicide. There are also reported cases where the scene prima facie appeared as that of homicide but on a closer look turned out to be suicidal. In all such cases a detailed investigation of the scene, reconstruction of the position of the suspended body, examination of the ligature material, type of knot, and direction of the fibers in case of rope helps in establishing manner of hanging.[2] To differentiate various types and manner of hanging a meticulous examination of the neck of the deceased with the internal structures is of immense value. Such findings assume tremendous importance whenever in doubt regarding the manner of hanging. In the case presented here, there were multiple turns of ligature around the neck. The findings aroused the

suspicion of homicide but the examination of scene of crime and other circumstantial evidences were of crucial importance while deciding the manner of death in this case.



Figure 1. Ligature Material in situ.

Case Report I

A 50 year old male was found dead in his unbolted room. The victim was found partially suspended with the help of telephone wire tied about 8 feet high to a hook on the ceiling. The victim was wearing a blue cloth around the waist, which was blood stained. Some dried blood also spattered on the floor around him. There were four grooves (ligature marks) around the neck; the first groove was 0.5 cm below the right ear, anteriorly it passed through the mouth and was 0.5 cm below left ear; the width of the groove was 0.5 cm and was made of one round of ligature material (telephone wire) as shown in (figure 1). The second groove was 4 cm below right ear, 7 cm below the chin and 4 cm below left ear; the width of the groove was 1cm and was made up of two rounds of wire. The third groove was present 9 cm below the right ear, 8 cm below the chin and 7 cm below left ear, the width of the groove was 4 cm and was made up of four rounds of wire. The fourth groove was present 14 cm below right ear, 11cm below the chin and 12 cm below left ear; the width of the groove was 0.5 cm and was made up of one round of wire.



Figure 2. Ligature Mark around the face and neck.

The knot was running type and was present below the right angle of jaw. No suicide note was found at the site. All these findings particularly the presence of loop of ligature in the mouth and face and presence of blood on the floor raised the suspicion of homicidal hanging. At autopsy, the deceased showed injuries consistent with the ligature hanging. These included a near circumferential ligature furrow about the neck which curved upwards to a point of suspension below right angle of jaw (figure 2). Internally on layer dissection of neck, no bruising of neck muscles and fracture of hyoid thyroid complex was seen (figure 3, 4). Anal examination revealed multiple hemorrhoids at 7'o clock and 11'o clock positions. The investigation of the scene, victim and witnesses revealed findings that supported the manner of death as suicide. Also there was no forced entry in the room. The autopsy findings were consistent with suicidal hanging. The blood on the floor and clothes was due to blood oozing out from the hemorrhoids due to increased venous pressure resulting from compression of neck veins. Thus after thorough investigation no evidence of any foul play was found. Cause of death was given due to ligature hanging. Additional information provided by the victim's friend revealed that the victim recently lost his job and his wife deserted him for another man.

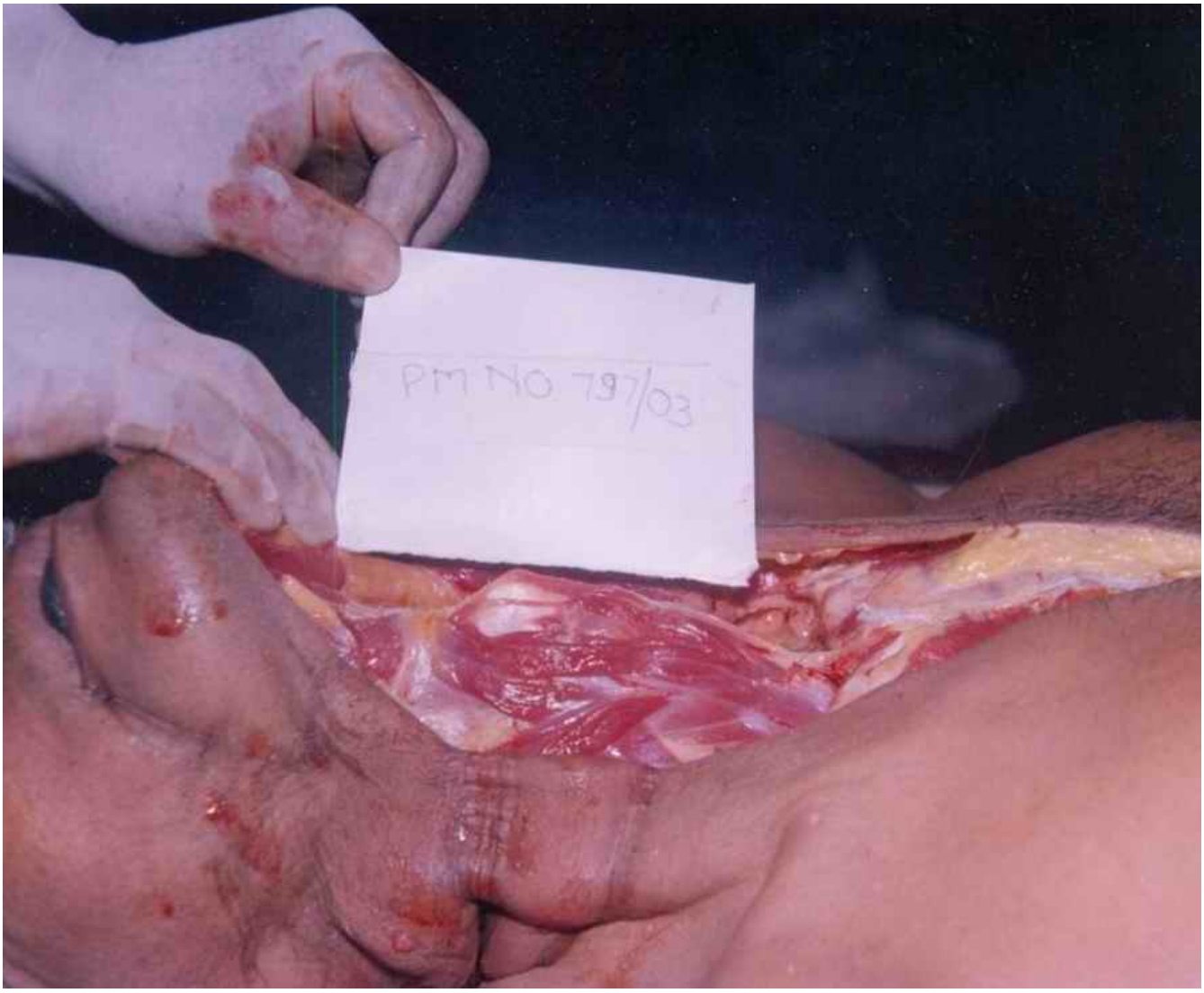

Figure 3. There was no effusion of blood in soft tissues and neck muscles.

Discussion

The death investigator can encounter a variety of staged crime scenes.[3] Suicide may be staged or even altered by family members or friends in an attempt to avoid embarrassment or for other personal, social or religious reasons. Staging a suicide as homicide by the victim by may be a final effort to gain notoriety or exert revenge against family or friends. In addition life insurance can be a factor. In most of the published case reports of suicide labeled as homicide victim mostly used firearm. Although this may be convenient and common method, other methods such as hanging, road traffic accidents and even drowning may be employed to accomplish the task. The paper describes 6 cases of suicidal hanging and 1 case of accidental where limbs of the victim were bound. This method of hangings always arouses a suspicion of homicide manner of death , therefore the forensic expert should pay particular attention to crime scene examination not to underestimate the value of careful investigation by the investigating agencies.[4] In the above-mentioned case, there were a number of factors, which indicate that the victim took his life. There was lack of defense wounds or signs of struggle over the body. Autopsy findings and other issues in the victim's personal life conflicted with the findings of homicide.

In this case, on visit to the scene of crime the finding of unbolted room, splashing of blood around the victim and the incomplete suspension of the body arose the suspicion of homicidal manner of hanging. On autopsy examination, the unusual presence of ligature mark around the face and neck and multiple turns of the ligature led us to consider whether the manner of death was suicide or homicide. Since in the majority of suicidal hangings, the noose consists of a single loop and less commonly two loops may be seen,[5] it is quite unusual to encounter a case with multiple turns of ligature around face and neck.

On further investigations from investigating officer it was revealed that the person had recently lost his job and his wife also deserted him, leaving him for another man. This was the reason behind the depression and his committing suicide. The internal examination of the neck structures revealed no bruising of neck structures and lack of fracture of hyoid-thyroid complex.

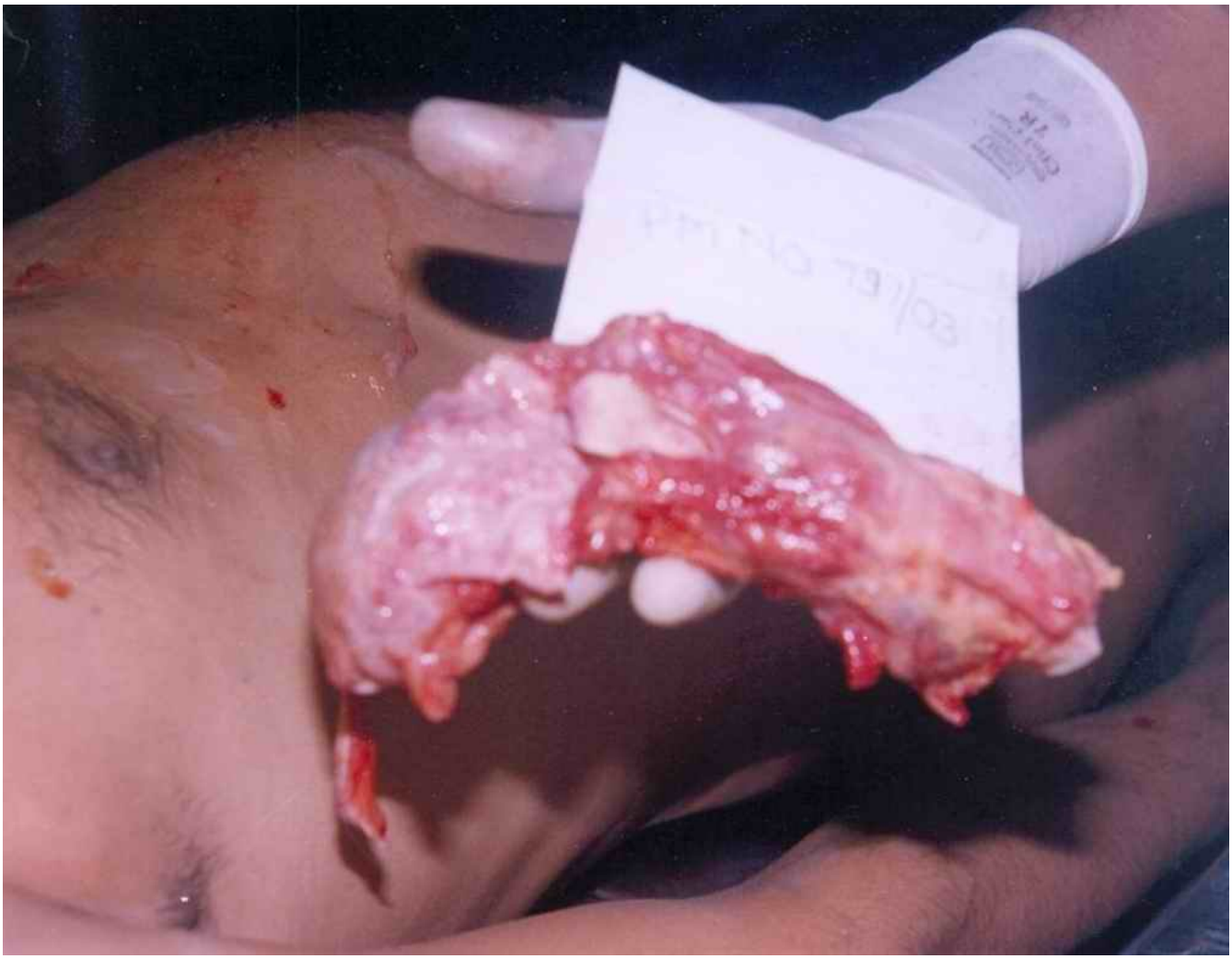

Figure 4. Internal structures of neck with no fractures of hyoid- thyroid complex

There are differences in the autopsy appearances of those who have died of hanging as the cause of death is not always the same. There can be blocking of the airways, occlusion of the circulation of brain or reflex vagal inhibition. The blockage or complete compression of airways is not necessary to cause death as even a small amount of pressure is enough to compress carotid arteries. Thus its possible for oneself to hang while sitting, kneeling or even lying down. This is so because the weight of the head against a noose is in itself sufficient to occlude carotid arteries and cause death. In our case the person was found in incompletely suspended position and autopsy examination

there was absence of congestion of face and neck above the ligature mark and petechiae of the eyelids and conjunctiva. We concluded that the most likely cause of death in this case was obstruction of arterial flow to the brain due to backpressure on carotid arteries.

References

1. Gunnell D, Bennewith O, Hawton K, Simkin S, Kapur N. The epidemiology and prevention of suicide by hanging: a systemic review. *Int J Epidemiol* 2005;34(2):433-42 (Back to [citation] in text)
2. Puschel K, Holtz W, Hildebrand E, Naeve W, Brinkmann B. Hanging –suicide or homicide. *Arch Kriminol* 1984;174:141-53. (Back to [citation] in text)
3. Adair TW, Dobersen MJ. A case of suicidal hanging staged as homicide. *J Forensic Sci* 1999 Nov;44(6): 1307-9 . (Back to [citation] in text)
4. Krzyzanowski M, Jankowski Z, Piesniak D, Wilmanowska. Cases of hanging with bound limbs-suicide, homicide or accident. *Arch Med Sadowej Kryminol* 2002;52(4):371-9 (Back to [citation] in text)
5. Vincent JDM, Dominick DM . Forensic Pathology. 2nd ed. United States of America: CRC Press; 2001. (Back to [citation] in text)